

Effect of propolis, alcohol and dexamethasone on mast cells in surgical skin wounds

Túlio Garcia Rocha,^a Poliana Ribeiro Barroso,^b MSc, Ricardo Lopes-Rocha,^c MSc, João Luiz de Miranda,^d PhD, Sandra Aparecida Marinho,^e PhD, Flaviana Dornela Verli,^d PhD

^aUndergraduate student, Pharmacy, Federal University of the Jequitinhonha and Mucuri Valleys (UFVJM), Diamantina, Minas Gerais, Brazil.

^bScience and Technology Institute (ICT), UFVJM.

^cDepartment of Dentistry, UFVJM.

^dDepartamento of Basic Sciences, Pathology Laboratory, UFVJM.

^eDepartment of Dentistry, State University of Paraíba, Araruna, Paraíba, Brazil.

Correspondence to: poliana.barroso@ict.ufvjm.edu.br

Keywords: anti-inflammatory, healing, mast cells, surgical wounds, propolis

Abstract

Background: The present study determines the anti-inflammatory effect of the topical application of ethanolic extract of commercial propolis, used in wound care, in the mast cell population in connective tissue during the initial healing process of surgical skin wounds.

Method: Sixty Wistar rats were divided into three experimental groups: Group 1 (n = 20) – 30% ethanolic extract of propolis; Group 2 (n = 20) – 70% alcohol; and Group 3 (n = 20) dexamethasone. Each substance was applied topically every 12 hours. The specimens were submitted to histological analysis with Toluidine Blue stain. Mast cell counts were performed using the Axio Vision[®] software program. Statistical analysis involved the Kruskal-Wallis and Mann-Whitney tests.

Results: Significantly smaller numbers of mast cells were found in the groups submitted to the propolis extract and 70% alcohol in comparison to dexamethasone (p < 0.0001). Moreover, the reduction in the number of mast cells was maintained in all healing phases in the propolis extract group.

Conclusion: The present findings demonstrate a possible anti-inflammatory property of propolis extract and 70% alcohol, which was more effective at reducing the mast cell population in surgical skin wounds at different postoperative times in comparison to the standard pharmacological treatment, dexamethasone.

© Medpharm

Wound Healing Southern Africa 2016;9(2):16-20

Introduction

The healing process of skin wounds requires the interaction of different types of cells, cytokines, growth factors and molecules of the extracellular matrix.^{1,2} Mast cells participate in the inflammation,^{3,4} cell proliferation^{5,6} and tissue remodelling⁷⁻¹¹ phases of healing. Mast cells are distributed in the points of sites of aggressive agents, such as the dermis and mucous membranes and are the first substances to respond to trauma and stimulate an immune response through the release of chemical mediators.^{9,11-13} In rodents, these cells are classified as mucosal mast cells and connective tissue mast cells, depending on the location and biochemical composition,^{14,15} which correspond to triptase and kinase mast cells in humans.¹⁶ These two mediators are mainly related to the proliferation and remodelling phases and are involved in the differentiation and activation of fibroblasts and myofibroblasts as well as the stimulation of collagen synthesis.^{11,17}

Certain agents, such as capybara oil,² lasers, light-emitting diodes,¹⁸ caffeic acid and derivatives,¹⁹ acai²⁰ and propolis²¹ are able to modulate the mast cell population. Barroso and co-workers²¹ found

that an ethanolic propolis extract was capable of reducing the number of oral mucosal mast cells in the early phases of inflammation.

The aim of the present study was to determine the anti-inflammatory effect of the topical application of ethanolic extract of commercial propolis, and controls (70% alcohol and dexamethasone) in the mast cell population in connective tissue during the initial healing process of surgical skin wounds.

Material and methods

Sample

This study was conducted in compliance with national and international norms regulating research involving animals and received approval from the Animal Research Ethics Committee of the Federal University of the Jequitinhonha and Mucuri Valleys (UFVJM), Diamantina, Minas Gerais, Brazil. Sixty male Wistar rats (*Rattus norvegicus albinus*) weighing 250 to 300 grams (mean age: 120 days) were acquired from the UFVJM animal lodging facility. Each animal was placed in a plastic cage (60 X 50 X 22 cm) lined with sawdust that was cleaned twice a week and kept at room temperature. The animals had free access to a balanced

ration (Nuvilab®) and water. A 12-hour light/dark photoperiod was maintained throughout the experiment.

Experimental groups and evaluation times

The animals were divided into three groups of 20 rats. Each group was subdivided into five subgroups of four rats for the histopathological analysis of surgical wounds on postoperative days 1, 3, 7, 14 and 28.

Surgical wound and topical application of substances

The animals were anaesthetised with an intraperitoneal injection of 20 mg/Kg of sodium thiopental® (Cristália, San Paulo, Brazil). The fur on the dorsum was cut with surgical scissors to expose a square patch of skin measuring approximately 5 X 5 cm. A surgical wound 1 mm in depth was performed using a punch measuring 1 cm in diameter.

The surgical wound in Group 1 (n = 20) received topical applications of a 30% ethanolic propolis extract (Apiário Mackllani Ltda, Saint Bárbara®, Minas Gerais, Brazil). Group 2 (n = 20) received topical applications of 70% alcohol (Miyako of Brasil Ltda, Guarulhos, San Paulo, Brazil). Group 3 (n = 20) received topical applications of a 0.1% dexamethasone cream (Lisoderme®, Belfar Pharmaceutical Industry, Belo Horizonte, Minas Gerais, Brazil). Each substance was applied every 12 hours using a number 1 camel hair brush (Tigre®, San Paulo, Brazil). Each application consisted of four consecutive brushings with no excess of the solutions.

The propolis extract was acquired from the local market and used undiluted. According to the manufacturer, the propolis extract was produced from 11.56% g/ml of dry Brazilian propolis extract. The total polyphenol and flavonoid content of the propolis extract solution and derived dry extract was determined at the UFVJM biochemical laboratory. Total phenol content was determined using the colorimetric method described by Folin-Ciocalteu.^{22,23} Total flavonoid content was determined using the method described by Park and co-workers²⁴ (Table I).

Euthanasia

Four animals from each group were euthanised on days 1, 3, 7, 14 and 28 following the application of the surgical wounds. They were anaesthetised with an intraperitoneal injection of 20 mg/Kg of sodium thiopental® (Cristália, São Paulo, Brazil). Skin samples were dried and fixed in a 10% formalin solution for 48 hours. The specimens were histologically processed, submitted to micrometer cuts and stained with Toluidine Blue.

Histopathological analysis

Mast cell counts were performed on slides using the Axio Vision® software program (Carl Zeiss, Germany). Images were captured at a magnification of 100 X with the aid of a digital camera (Axio Cam®, Carl Zeiss, Germany) coupled to an optical microscope (Primo Star®, Carl Zeiss, Germany). Two slides were examined for each sample. The mast cell count was performed in four histological squares – two located on the edges and two located in the centre of the surgical wound (Figure 1). Each histological field had an area of 924.93 µm².

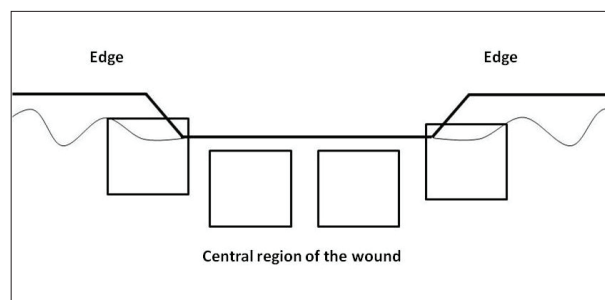


Figure 1. Schematic representation of square histological fields in which mast cells were counted

Statistical analysis

In the exploratory analysis of the data, the means did not demonstrate normal distribution. Thus, the nonparametric Kruskal-Wallis and Mann-Whitney tests were used for the comparison of the groups. For both tests, a value of P < 0.05 was considered as statistically significant.

Results

Table II displays the median values and confidence intervals of the mast cell counts. Statistically significant differences were found among the groups at the different postoperative evaluation times.

Discussion

Studies have shown that connective tissue mast cells play a key role in all phases of the wound healing process.^{3,7-11} Only Nauta and co-workers²⁵ report that mast cells are not required for the healing of excisional skin wounds in rats, but the animals in question were genetically modified and mast cell deficient; moreover, the animals exhibited other blood abnormalities, such as anaemia, which may

Table I. Total polyphenol and flavonoid content of the propolis extract solution and derived dry extract

| Extract | Total polyphenol content | | Total flavonoid content | | Anthocyanin |
|---------------------------|--------------------------|---------|-------------------------|----------|-------------|
| | (mg/ml) | (mg/g)* | (mg/ml) | (mg/g)** | |
| Propolis extract solution | 19.52 ± 0.07 | – | 19.06 ± 0.64 | – | 1.61 ± 0.25 |
| Dry propolis extract*** | – | 117.16 | – | 114.4 | – |

*Polyphenols (g/l) equivalent to gallic acid

**Flavonoids (g/l) equivalent to quercetin

***Dry extract obtained through freeze drying of ethanolic and aqueous propolis extracts with the same commercial presentation

©Apiário Mackllani Ltda, Saint Bárbara, Minas Gerais, Brazil

Table II. Mast cell counts in surgical wounds submitted to topical application of different substances at different evaluation times and comparisons among groups

| Postoperative evaluation (n) | Groups (n=60) | | | G1 X G2 X G3 | G1 X G2 | G1 X G3 | G2 X G3 |
|------------------------------|--------------------------------------|-----------------------------|------------------------------------|--------------|---------|-----------|-----------|
| | Group 1 (n = 20) Propolis extract | Group 2 (n = 20) Alcohol | Group G3 (n = 20) Dexamethasone | | | | |
| | Median (95% confidence interval) | | | | | | |
| Day 1 (n = 4) | 11.0 (10.08 – 13.67) | 10.0 (10.24 – 14.58) | 24.0 (19.82 – 30.60) | < 0.0001** | 0.90 | < 0.0001# | < 0.0001# |
| Day 3 (n = 4) | 12.0 (9.92 – 16.71) | 11.5 (10.42 – 14.83) | 13.5 (11.02 – 15.11) | 0.83 | – | – | – |
| Day 7 (n = 4) | 12.0 (11.14 – 14.36) | 10.5 (10.28 – 16.29) | 22.0 (20.51 – 24.68) | < 0.0001** | 0.45 | < 0.0001# | < 0.0001# |
| Day 14 (n = 4) | 12.5 (11.65 – 15.60) | 9.0 (8.03 – 11.84) | 18.0 (15.99 – 22.63) | < 0.0001** | 0.005# | 0.006# | < 0.0001# |
| Day 28 (n = 4) | 17.5 (15.46 – 26.42) | 19.0 (16.05 – 20.26) | 14.0 (11.54 – 16.65) | 0.032** | 0.97 | 0.055 | 0.009# |

**Statistically significant difference among groups (Kruskal-Wallis test)

#Statistically significant difference in pair-by-pair comparison (Mann-Whitney test)

have exerted an influence on the healing process.¹¹ Considering this controversy and the need to develop effective anti-inflammatory agents, further studies are necessary for the evaluation of the wound healing process.

With this approach, we know that connective tissue mast cells are the first substances to respond to trauma and stimulate the release of pre-formed, biosynthesised chemical mediators,^{11,12} such as inflammatory mediators (histamine, heparin, TNF- α and IL-1), growth factors (TGF- β 1 and PDGF) and proteases (serine, chymase and tryptase).^{3,9,26} However, the intensive participation of connective tissue mast cells and mediators has also been implicated in adverse health conditions, such as an excessive inflammatory response,¹¹ anaphylaxis,²⁷ hypertrophic scars²⁸ and other pathological fibroses.²⁹ Thus, therapeutic strategies for the neutralisation of the harmful effects of connective tissue mast cells should be developed.³⁰

According to Chen and co-workers,¹¹ the inhibition of mast cells through pharmacological action is desirable throughout the wound healing process to allow better collagen organisation and diminish the risk of scar formation. In the present study, the propolis extract demonstrated considerable potential in reducing the number of connective tissue mast cells in all phases of the healing process and was more effective than the conventional anti-inflammatory agent dexamethasone. This is in agreement with data described by Abreu and co-workers,³¹ who found that the topical application of an ethanolic propolis extract accelerated the deposition of collagen in skin wounds. According to the authors, this occurred due to the anti-inflammatory action of the propolis extract as well as the greater stimulation of type I collagen. Moreover, the propolis extract promoted the complete reepithelisation of the wound by Day 14, whereas reepithelisation was only partial after Day 28 with dexamethasone.

The use of natural products and novel treatments that can favour wound healing has been evaluated in previous studies,^{2,18-21,32-33} especially ethanolic propolis extract.^{21,31} Both Horiguchi *et al*²⁰ and Barroso *et al*²¹ report the inhibition of connective tissue mast cells due to compounds found in natural products, such as flavonoids and other phenolic compounds, as observed in the chemical composition from ethanolic propolis extract used in the present study.

Barroso *et al*²¹ found that propolis extract was able to reduce the number of mast cells in the early phases of inflammation in oral wounds. In the present study, the propolis extract also inhibited connective tissue mast cells in later phases of the skin healing process. This divergence may be related to the structural and biochemical differences in the mast cells evaluated,^{14,16} where, in the previous study, mucosal mast cells were studied, and in the present investigation connective mast cells in skin were analysed.

It is important for the healing process to proceed without infection.^{34,35} Both propolis extract³⁶ and alcohol³⁷ are considered effective antiseptic agents. The antimicrobial activity of alcohol is favoured in an aqueous solution ranging from 60 to 90%, which leads to biochemical disorders in microbial cells.³⁸ In the present study, a statistically significant reduction ($p < 0.0001$) in the number of connective tissue mast cells was found in the early phases of inflammation in the group of rats submitted to 70% alcohol, which may be attributed to the antiseptic action of this substance.

The positive control, dexamethasone, demonstrated a late-onset effect, with a greater reduction in the number of connective tissue mast cells at the end of the experiment in comparison to the other substances. This finding demonstrates that the propolis extract and alcohol were more effective anti-inflammatory agents in the early phases of the healing process than dexamethasone. The late-onset action of dexamethasone may be related to the mechanism of action of glucocorticoids, which exhibit anti-inflammatory activity through

the repression of pro-inflammatory genes and the induction of anti-inflammatory genes.³⁹⁻⁴² However, this repression and induction mechanism is rather slow, which may explain the late-onset anti-inflammatory action of dexamethasone.

Dexamethasone led to a significantly greater reduction in the number of mast cells on Day 28 in comparison to the group that received 70% alcohol ($p < 0.009$), but the same did not occur in comparison to the group that received the propolis extract. These findings are in agreement with data described by Barroso and co-workers²¹ and further underscore the late-onset anti-inflammatory activity of dexamethasone in the wound healing process. The prolongation of the mobilisation of mast cells after 21 days postoperatively hinders the formation of granulation tissue^{2,43} and the excess of connective tissue mast cell mediators, such as kinase and tryptase, can exert a negative impact on the migration of epithelial cells,^{2,44-45} augment the activation of fibroblasts and favour the exacerbated deposition of collagen.^{11,17,28-29} The propolis extract led to a reduction in the number of connective tissue mast cells in both the early and late phases of the repair process, which favoured adequate tissue recovery.

The healing potential of propolis has been reported in previous studies.^{20,31,46-48} Kilicoglu and co-workers⁴⁶ demonstrated that the gavage administration of propolis accelerated the healing of anastomosis in the colon of rats. The authors suggest that the mechanism of action is associated with the inhibition of the inflammatory response as well as the stimulation of collagen synthesis. In the present study, the propolis extract accelerated the skin wound healing process due to the reduction in the inflammatory response. Abreu and co-workers³¹ also found that propolis extract favoured the deposition of collagen in skin wounds, thereby confirming its anti-inflammatory activity observed in this study.

Conclusion

The present findings demonstrate the anti-inflammatory properties of commercial propolis extract and of 70% alcohol, demonstrating that the popular use of this propolis extract is efficient in the healing process. Since, the commercial propolis extract was more effective at reducing the mast cell population in the acute inflammation phase following surgical skin wounds in comparison to the pharmacological standard, dexamethasone. Moreover, propolis also demonstrated an effect on mast cells in the late stage of the tissue repair process.

Conflict of interest

The authors declare that they have no competing interests.

References

- Li J, Chen J, Kirsner R. Pathophysiology of acute wound healing. *Clin Dermatol* 2007;25:9–18.
- Marinho PC, Neto-Ferreira R, Carvalho JJ. Evaluation of therapeutic intervention with a natural product in cutaneous wound healing: the use of capybara oil. *Evid Based Complement Alternat Med* 2013;2013:1–10.
- Egozi EI, Ferreira AM, Burns AL, et al. Mast cells modulate the inflammatory but not the proliferative response in healing wounds. *Wound Repair Regen* 2003;11:46–54.
- Martin P1, Leibovich SJ. Inflammatory cells during wound repair: the good, the bad and the ugly. *Trends Cell Biol* 2005;15:599–607.
- Norrbay K. Mast cells and angiogenesis. *APMIS* 2002;110:355–71.
- Nienartowicz A, Sobaniec-Kotowska ME, Jaroicka-Cyrta E, Lemancewicz D. Mast cells in neoangiogenesis. *Med Sci Monit* 2006;12:RA53–6.
- Nishikori Y1, Kakizoe E, Kobayashi Y, Shimoura K, Okunishi H, Dekio S. Skin mast cell promotion of matrix remodeling in burn wound healing in mice: relevance of chymase. *Arch Dermatol Res* 1998;290:553–60.
- Iba Y1, Shibata A, Kato M, Masukawa T. Possible involvement of mast cells in collagen remodeling in the late phase of cutaneous wound healing in mice. *Int Immunopharmacol* 2004;4:1873–80.
- Ng MF. The role of mast cells in wound healing. *Int Wound J* 2010;7:55–61.
- Douaiher J, Succar J, Lancerotto L, et al. Development of mast cells and importance of their tryptase and chymase serine proteases in inflammation and wound healing. *Adv Immunol* 2014;122:211–52.
- Chen L, Schrementi ME, Ranzer MJ, et al. Blockade of mast cell activation reduces cutaneous scar formation. *PLoS One* 2014;9:e85226.
- Artuc M, Hermes B, Steckelings UM, et al. Mast cells and their mediators in cutaneous wound healing—active participants or innocent bystanders? *Exp Dermatol* 1999;8:1–16.
- Steinhoff M, Corvera CU, Thoma MS, et al. Proteinase-activated receptor-2 in human skin: tissue distribution and activation of keratinocytes by mast cell tryptase. *Exp Dermatol* 1999;8:282–94.
- Forsythe P, Ennis M. Clinical consequences of mast cell heterogeneity. *Inflamm Res* 2000;49:147–54.
- Yong LC. The mast cell: origin, morphology, distribution, and function. *Exp Toxicol Pathol* 1997;49:409–24.
- Noli C, Miolo A. The role of mast cells in the early stages of wound healing. *Int Wound J* 2010;7:540.
- Bayat M, Vasheghani MM, Razavie N, Jalili MR. Effects of low-level laser therapy on mast cell number and degranulation in third-degree burns of rats. *J Rehabil Res Dev* 2008;45:931–8.
- De Castro IC1, Rocha CA, Gomes Henriques AC, et al. Do laser and led phototherapies influence mast cells and myofibroblasts to produce collagen? *Lasers Med Sci* 2014;29:1405–10.
- Nader MA. Caffeic acid phenethyl ester attenuates IgE-induced immediate allergic reaction. *Inflammopharmacology* 2013;21:169–76.
- Horiguchi T, Ishiguro N, Chihara K, et al. Inhibitory effect of açai (*Euterpe oleracea* Mart.) pulp on IgE-mediated mast cell activation. *J Agric Food Chem* 2011;59:5595–601.
- Barroso PR, Lopes-Rocha R, Pereira EM, et al. Effect of propolis on mast cells in wound healing. *Inflammopharmacology* 2012;20:289–94.
- Singleton VL, Orthofer R, Raventós RML. Analysis of total phenols and other oxidation substrates and antioxidants by means of Folin-Ciocalteu reagent. *Methods Enzymol* 1999;299:152–78.
- Andrade CA, Costa CK, Bora K, et al. Determinação do conteúdo fenólico e avaliação da atividade antioxidante de *Acácia podalyriifolia* A. Cunn. ex G. Don, *Leguminosae-mimosoideae*. *Rev Bras Farmacogn* 2007;17:231–5.
- Park YK, Koo MH, Sato HH, Contado JL. Survey of some components of propolis which were collected by *Apis mellifera* in Brazil. *Arq Biol Tecnol* 1995;38:1253–9. [In Press]
- Nauta AC, Grova M, Montoro DT, et al. Evidence that mast cells are not required for healing of splinted cutaneous excisional wounds in mice. *PLoS One* 2013;8:e59167.
- Walsh LJ. Mast cells and oral inflammation. *Crit Rev Oral Biol Med* 2003;14:188–98.
- Picard M, Giavina-Bianchi P, Mezzano V, Castells M. Expanding spectrum of mast cell activation disorders: monoclonal and idiopathic mast cell activation syndromes. *Clin Ther* 2013;35:548–62.
- Huttunen M, Aalto ML, Harvima RJ, et al. Alterations in mast cells showing tryptase and chymase activity in epithelializing and chronic wounds. *Exp Dermatol* 2000;9:258–65.
- Desmoulière A, Chaponnier C, Gabbiani G. Tissue repair, contraction, and the myofibroblast. *Wound Repair Regen* 2005;13:7–12.
- Lundequist A, Pejler G. Biological implications of preformed mast cell mediators. *Cell Mol Life Sci* 2011;68:965–75.
- Abreu AM, Douglas de Oliveira DW, Marinho SA, et al. Effect of topical application of different substances on fibroplasia in cutaneous surgical wounds. *ISRN Dermatol* 2012;2012:282973.
- Qiu XW1, Wang JH, Fang XW, et al. Anti-inflammatory activity and healing-promoting effects of topical application of emu oil on wound in scalded rats. *Di Yi Jun Yi Da Xue Xue Bao* 2005;25:407–10.
- Ghaderi R, Afshar M, Akhbarie H, Gholipour MJ. Comparison of the efficacy of honey and animal oil in accelerating healing of full thickness wound of mice skin. *Int J Morphol [online]* 2010;28:193–8.
- Percival SL, Cutting KF. Biofilms: possible strategies for suppression in chronic wounds. *Nurs Stand* 2009;23:64. [In Press]
- Ousey K, McIntosh C. Topical antimicrobial agents for the treatment of chronic

- wounds. *Br J Community Nurs* 2009;14:6–10.
36. Bonvehí JS, Coll FV, Jorda RE. The composition, active components and bacteriostatic activity of propolis in dietetics. *JAOCs* 1994;71:529–32.
 37. Trampuz A, Widmer AF. Hand hygiene: a frequently missed lifesaving opportunity during patient care. *Mayo Clin Proc* 2004;79:109–16.
 38. Rochon-Edouard S, Pons JL, Veber B, et al. Comparative in vitro and in vivo study of nine alcohol-based handrubs. *Am J Infect Control* 2004;32:200–4.
 39. Barnes P. Anti-inflammatory actions of glucocorticoids: molecular mechanisms. *Clin Science* 1998;94:557–72.
 40. Joyce DA, Gimblett G, Steer JH. Targets of glucocorticoid action on TNF-alpha release by macrophages. *Inflamm Res* 2001;50:337–40.
 41. Saklatvala J. Glucocorticoids: do we know how they work? *Arthritis Res* 2002;4:146–50.
 42. Rhen T, Cidlowski JA. Antiinflammatory action of glucocorticoids-new mechanisms for old drugs. *N Engl J Med* 2005;353:1711–23.
 43. Souza BR, Santos JS, Costa AM. Blockade of beta1- and beta2-adrenoceptors delays wound contraction and re-epithelialization in rats. *Clin Exp Pharmacol Physiol* 2006;33:421–30.
 44. Cardoso JF, Souza BR, Amadeu TP, et al. Effects of cigarette smoke in mice wound healing is strain dependent. *Toxicol Pathol* 2007;35:890–6.
 45. Ebihara N, Funaki T, Murakami A, et al. Mast cell chymase decreases the barrier function and inhibits the migration of corneal epithelial cells. *Curr Eye Res* 2005;30:1061–9.
 46. Kilicoglu SS, Kilicoglu B, Erdemli E. Ultrastructural view of colon anastomosis under propolis effect by transmission electron microscopy. *World J Gastroenterol* 2008;14:4763–70.
 47. Song HS, Park TW, Sohn UD, et al. The Effect of Caffeic Acid on Wound Healing in Skin-incised Mice. *Korean J Physiol Pharmacol* 2008;12:343–7.
 48. Paulino N, Abreu SR, Uto Y, et al. Anti-inflammatory effects of a bioavailable compound, Artepillin C, in Brazilian propolis. *Eur J Pharmacol* 2008;587:296–301.